

AMERICAN JOURNAL OF OPHTHALMOLOGY®

VOLUME 144

CLINICAL CHARACTERISTICS OF EXUDATIVE AGE-RELATED MACULAR DEGENERATION IN JAPANESE PATIENTS

Maruko, Iida, Saito, and Co-Authors

RETINAL BREAKS OBSERVED DURING PARS PLANA VITRECTOMY

Moore, Kitchens, Smiddy, and Co-Authors

INTERFERON- α AS AN EFFECTIVE TREATMENT FOR NONINFECTIOUS POSTERIOR UVEITIS AND PANUVEITIS

Plskova, Greiner, and Forrester

LONG-TERM RESULTS OF AHMED GLAUCOMA VALVE IMPLANTATION FOR UVEITIC GLAUCOMA

Papadaki, Zacharopoulos, Pasquale, and Co-Authors

THE RISK OF RETINAL DETACHMENT IN HIGH MYOPIA AFTER SMALL INCISION COAXIAL PHACOEMULSIFICATION

Alio, Ruiz-Moreno, Shabayek, and Co-Authors

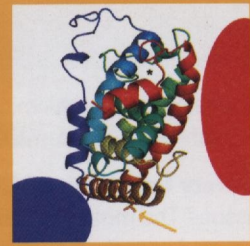
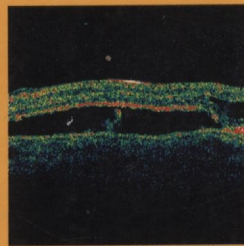
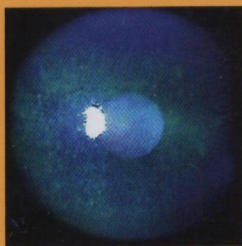
EDITORIALS

STATINS AND AGE-RELATED MACULAR DEGENERATION: TIME FOR A RANDOMIZED CONTROLLED TRIAL?

Wong and Rogers

SELECTIVE vs ARGON LASER TRABECULOPLASTY: CONTROVERSY IN EVOLUTION

Girkin



AJO®

MONTHLY SINCE 1884

Full-text online at AJO.com

ELSEVIER

ISSN 0002-9394

AMERICAN JOURNAL OF OPHTHALMOLOGY®

ISSN 0002-9394 • VOL. 144, NO. 1 JULY 2007

CONTENTS

Continued from page A7

- 134 The effect of intravitreal triamcinolone on foveal edema in exudative macular degeneration. *Mark C. Gillies and Jorgen Larsson*
- 136 Long-term success in the correction of exposed glaucoma drainage tubes with a tube extender. *Kevin D. Merrill, Abraham W. Suhr, and Michele C. Lim*
- 137 Mist delivery of eye medication to the anterior segment. *James F. Collins, Darlene A. Dartt, and Reza Dana*
- 139 Autologous plasmin-assisted vitrectomy for stage 5 retinopathy of prematurity: a preliminary trial. *Yasutomo Tsukahara, Shigeru Honda, Hisanori Imai, Naoshi Kondo, Shigeki Fujii, Naoki Yokoyama, Akira Hirata, Takahiro Kawaji, Mikiko Fukushima, Hidenobu Tanihara, and Akira Negi*
- 141 A method for noncontact measurement of corneal diameter in children. *Wolf A. Lagrèze and Gergely Zobor*
- 143 Glistenings in the single-piece, hydrophobic, acrylic intraocular lenses. *Aaron Waite, Nathan Faulkner, and Randall J. Olson*
- 144 Traumatic lenticular abscess: clinical description and outcome. *Revathi Rajaraman, Prajna Lalitha, Anita Raghavan, Manikandan Palanisamy, and Namperumalsamy Venkatesh Prajna*
- 146 Prostaglandin E₂ inhibition and aqueous concentration of Ketorolac 0.4% (Acular LS) and Nepafenac 0.1% (Nevanac) in patients undergoing phacoemulsification. *Frank A. Bucci, Jr, L. David Waterbury, and Loretta M. Amico*
- 148 High incidence of autoimmune disease in Japanese patients with ocular adnexal reactive lymphoid hyperplasia. *Toshinobu Kubota and Suzuko Moritani*
- 149 Ocular involvement in pemphigus. *Giovanni Maria Palleschi, Barbara Giomi, and Paolo Fabbri*
- 152 Corneal thickness and relating factors in a population-based study in Japan: the Tajimi study. *Aisuo Tomidokoro, Makoto Araie, Aiko Iwase, and the Tajimi Study Group*
- 154 Ectatic disorders associated with a claw-shaped pattern on corneal topography. *Brandon W. Lee, Ula V. Jurkunas, Mona Harissi-Dagher, Antony M. Poothullil, Faisal M. Tobaigy, and Dimitri T. Azar*
- 157 Atypical mild enhanced S-cone syndrome with novel compound heterozygosity of the NR2E3 gene. *Byron L. Lam, Jeffrey L. Goldberg, Kristen L. Hartley, Edwin M. Stone, and Mu Liu*

CORRESPONDENCE

- 160 Incidence of fellow eye retinal detachment resulting from macular hole. *Zhou Peng, Zhao Ming-Wei, and Li Xiao-Xin*
- 160 Reply. *Yoshinori Oie and Kazuyuki Emi*
- 160 Meibomitis-related keratoconjunctivitis in childhood and adolescence. *Tomo Suzuki and Shigeru Kinoshita*
- 161 Reply. *Serge Doan*
- 161 Prevention of exposure of porous orbital implants following enucleation. *Milind N. Naik, Raman Mittal, Ramesh K. Murthy, and Santosh G. Honavar*
- 162 Reply. *Jia-Kang Wang, Shu-Lang Liao, Pei-Ching Lai, and Luke L. K. Lin*
- 162 Identification of scanning slit-beam topographic parameters important in distinguishing normal from keratoconic corneal morphologic features. *Afsun Sahin, Hikmet Basmak, and*