

# AMERICAN JOURNAL OF OPHTHALMOLOGY®

VOLUME 148

**THE AS-NEEDED TREATMENT STRATEGY FOR CHOROIDAL NEOVASCULARIZATION:  
A FEEDBACK-BASED TREATMENT SYSTEM**

Spaide

**ACANTHAMOEBA KERATITIS ASSOCIATED WITH CONTACT LENS WEAR IN SINGAPORE**

Por, Mehta, Chua, and Co-Authors

**VITREOUS PENETRATION OF ORALLY ADMINISTERED FAMCICLOVIR**

Chong, Johnson, Huynh, and Co-Authors

**VITREOMACULAR ADHESION IN ACTIVE AND END-STAGE AGE-RELATED  
MACULAR DEGENERATION**

Robison, Krebs, Binder, and Co-Authors

**EFFECTIVENESS OF TREATMENTS FOR METASTATIC UVEAL MELANOMA**


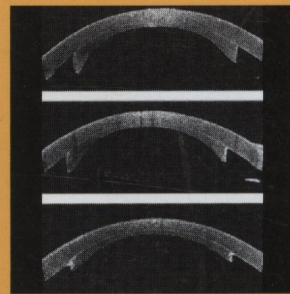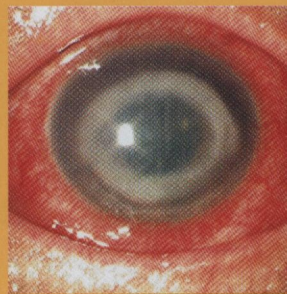
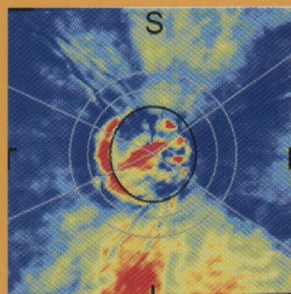
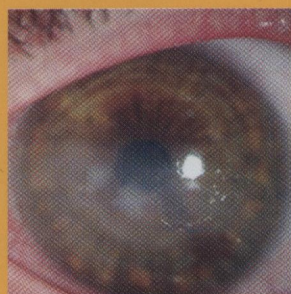
Augsburger, Corrêa, and Shaikh

**SPEED OF TELEMEDICINE vs OPHTHALMOSCOPY FOR RETINOPATHY OF  
PREMATURITY DIAGNOSIS**

Richter, Sun, Lee, and Co-Authors

**VISUAL PERFORMANCE AFTER IMPLANTABLE COLLAMER LENS IMPLANTATION AND  
WAVEFRONT-GUIDED LASER IN SITU KERATOMILEUSIS FOR HIGH MYOPIA**

Igarashi, Kamiya, Shimizu, and Komatsu



**AJO®**

MONTHLY SINCE 1884  
Full-text online at [www.ajo.com](http://www.ajo.com)

**ELSEVIER**

ISSN 0002-9394



# AMERICAN JOURNAL OF OPHTHALMOLOGY®

ISSN 0002-9394 • VOL. 148, NO. 4 OCTOBER 2009

## CONTENTS

### EDITORIALS

- 477 Molecular genetics and the classification of the corneal dystrophies: what is next? *Jayne S. Weiss*
- 479 Fuchs heterochromic iridocyclitis—syndrome, disease, or both? *Emmett T. Cunningham, Jr and Edoardo Baglivo*
- 482 Thessaloniki Eye Study: the importance of recognizing pseudoexfoliation. *Richard K. Parrish II*

### SERIES ON STATISTICS

- 484 Risk comparisons. *Nicholas P. Jewell*

### PERSPECTIVE

- 487 Acanthamoeba keratitis: diagnosis and treatment update 2009. *John K. G. Dart, Valerie P. J. Saw, and Simon Kilvington*

Acanthamoeba keratitis (AK) has a good prognosis if diagnosed early and treated appropriately. Confocal microscopy can be used to make a provisional diagnosis but a tissue diagnosis is recommended, especially for unresponsive cases. Topical biguanides are the only consistently effective drugs against the Acanthamoeba cyst that is the cause of persistent infection; other antimicrobials may have no role in treatment. Topical and systemic anti-inflammatory therapy for severe AK is controversial but may be effective.

### ORIGINAL ARTICLES

- 500 Azathioprine for ocular inflammatory diseases. *Sirichai Pasadhika, John H. Kempen, Craig W. Newcomb, Teresa L. Liesegang, Siddharth S. Pujari, James T. Rosenbaum, Jennifer E. Thorne, C. Stephen Foster, Douglas A. Jabs, Grace A. Levy-Clarke, Robert B. Nussenblatt, and Eric B. Suhler*

This retrospective cohort study of 145 ocular inflammatory diseases patients followed up from initiation of azathioprine as a single noncorticosteroid immunosuppressive drug found that azathioprine was moderately effective, with 41% achieving complete control of inflammation for at least 28 days within the first 6 months of therapy and 62% achieving complete control within 12 months. Approximately one-fourth of patients experienced treatment-limiting side effects within 1 year, but typically these side effects were reversible; most patients tolerated therapy.

- 510 A cross-sectional and longitudinal study of Fuchs uveitis syndrome in Turkish patients. *Ilknur Tugal-Tutkun, Esra Güney-Tefekli, Fulya Kamaci-Duman, and Isik Corum*
- A retrospective analysis of 172 Turkish patients with Fuchs uveitis syndrome suggests that diffuse medium-sized round keratic precipitates, low flare readings, iris stromal atrophy without hypochromia, and vitreous opacities in the absence of macular edema are more often helpful clues to the diagnosis than heterochromia in this population. Longitudinal data show that the risk of cataract development is much higher than the risk of glaucoma in patients followed without any treatment.

AJO®